

# Endovenous Laser: A New Minimally Invasive Method of Treatment for Varicose Veins—Preliminary Observations Using an 810 nm Diode Laser

LUIS NAVARRO, MD,\* ROBERT J. MIN, MD,<sup>†</sup> AND CARLOS BONÉ, MD<sup>‡</sup>

\**Vein Treatment Center and Beth Israel Medical Center, New York, New York, †Cornell Vascular, New York, New York, and ‡The Vein Treatment Center, Palma, Spain*

**BACKGROUND.** Long-term success in the treatment of truncal and significant branch leg varicosities, when the saphenofemoral junction (SFJ) and the greater saphenous vein (GSV) are involved, depends on the elimination of the highest point of reflux and the incompetent venous segment, and is best achieved by surgical ligation and stripping. Minimally invasive alternatives in the treatment of varicose veins with SFJ and GSV incompetence have been tried over the years to increase patient comfort, reduce cost and risk, and allow implementation by a wide variety of practitioners resulting in varying degrees of success depending on the fulfillment of the above two premises and the effectiveness of the method used.

**OBJECTIVE.** To demonstrate a novel way to use laser energy through an endoluminal laser fiber for the minimally invasive treatment of truncal varicosities that eliminates the highest point of reflux and the incompetent segment.

**METHODS.** Patients were treated with 810 nm diode laser energy administered endovenously through a bare-tipped laser fiber (400–750  $\mu$ m). Vein access for endoluminal placement of

the fiber through a catheter was achieved by means of percutaneous or stab wound incision under ultrasound guidance and local anesthesia. Exact placement of the fiber was determined by direct observation of the aiming beam through the skin and by ultrasound confirmation.

**RESULTS.** Preliminary short-term postprocedure results (up to 1 year, 2 months after treatment) in the endovenous laser treatment of 40 greater saphenous veins in 33 patients indicate a 100% rate of closure with no significant complications. In addition, a 2-year experience of 80 cases of isolated branch varicosities (Giacomini, anterolateral branch, etc.) also shows a 100% rate of closure.

**CONCLUSION.** Early results of our endoluminal laser methodology indicate a very effective and safe way to eliminate SFJ incompetence and close the GSV. With proper patient selection, the ease of methodology and the reduced risk and cost associated with endovenous laser treatment may make it a successful minimally invasive alternative for a wide group of patients that previously would have required ligation and stripping.

**SUCCESSFUL LONG-TERM** results in the treatment of primary leg varicose veins of truncal origin depend on two hemodynamic premises: the elimination of the highest point of reflux, and the elimination of the incompetent venous segment.<sup>1–7</sup> Surgical ligation and stripping has proven to be the most successful treatment method for truncal varicosities when the saphenofemoral junction (SFJ) and the greater saphenous vein (GSV) are incompetent.<sup>1,8–14</sup> Treatments of choice for varicose veins of nontruncal origin, such as perforator, pudendal, etc., are sclerotherapy and ambulatory phlebectomy.<sup>15,16</sup>

The drawbacks of traditional surgery include increased risk associated with extensive anesthesia, increased cost of hospitalization, and possible complications from surgery (including paresthesias). These

have been addressed by today's ligation and stripping, performed on an ambulatory basis with groin to knee invaginating stripping and concomitant branch mini-phlebectomy under a minor form of anesthesia.<sup>17–21</sup> Even so, safe and complete dissection of the SFJ requires a qualified surgeon, an equipped operating theater in a hospital, ambulatory surgical unit, or office, and some form of anesthesia beyond strictly local.

Given the above requirements and the typical patient aversion to surgery, minimally invasive alternatives, such as sclerotherapy, mini-phlebectomy, ultrasound- and transcatheter-guided sclerotherapy, and monopolar and bipolar radio frequency, are being utilized in the treatment of truncal varicosities in an effort to improve patient comfort, reduce cost and risk, and allow implementation by a variety of practitioners in different specialties. However, these procedures have had varied results, depending on the fulfillment of the above hemodynamic premises and the effectiveness of the method used to this end.<sup>22–30</sup>

Simple traditional sclerotherapy and mini-phlebectomy are best used for targeted branch varicosities, and

L. Navarro, MD, R.J. Min, MD, and C. Boné, MD have indicated no significant interest with commercial supporters.

Address correspondence and reprint requests to: Luis Navarro, MD, The Vein Treatment Center, 327 East 65th St., New York, NY 10021.



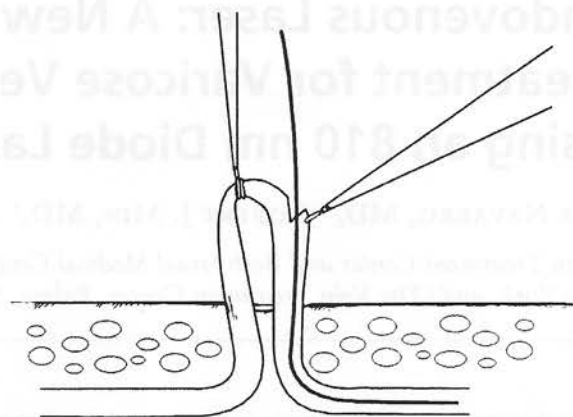
although they are occasionally employed to address the highest point of reflux, the SFJ, these techniques are difficult to use to this end. Modern reflux-oriented sclerotherapy techniques under ultrasound guidance (needle and transcatheter) are successfully replacing simple traditional sclerotherapy for reflux control but still report varying rates of recanalization, 10–42% in 1 year,<sup>31</sup> depending on the operator, technique, and sclerosant used. The use of iodinated solutions and of detergent sclerosing agents in the form of microfoam seem to produce more consistent sclerotherapy results.<sup>32</sup>

Other modern minimally invasive techniques use heat in the form of radio frequency or laser energy to close the GSV at the SFJ. In its initial trials, radio-frequency occlusion of the GSV has had successful closure rates of 90–95% (mean follow-up time 4.9 months), but a variety of heat-related complications involving the skin surround GSV structures.<sup>29</sup> These complications are in the process of being addressed by a temperature feedback mechanism and tumescent anesthesia.<sup>33</sup>

Since 1998, Spanish phlebologist Dr. Carlos Boné has employed and reported<sup>34</sup> (Boné C, presentation entitled "Endoluminal treatment of varicose veins with diode laser," Union International of Phlebology, Bremen, October 1999) on a new method to treat varicose veins and truncal varicosities with laser energy delivered endovenously via fiberoptic laser fiber. The following is a report of this method with preliminary results as used in Spain by Dr. Boné and in New York (since 1999) by the remaining authors. An institutional review board approved study (Chesapeake Research Review, Inc.) has been undertaken in New York to evaluate the safety and efficacy of this method for truncal varicose veins.

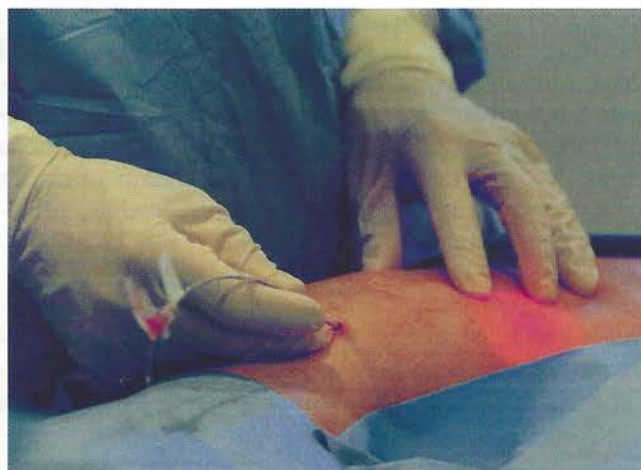## Methods

Thirty-three patients with SFJ reflux associated with GSV incompetence and enlargement of branch varicosities were given a choice of surgical ligation and stripping, transcatheter duplex-guided sclerotherapy, or endovenous laser treatment. Pretreatment transverse GSV measurements ranged from 4.7 mm × 4.3 mm to 16.0 mm × 21.6 mm (mean 10.2 mm × 10.6 mm). There were no GSV size limitations when determining candidates. General exclusion criteria included pregnancy or breast-feeding, an inability to ambulate, deep vein thrombosis, hypercoagulability, arterial occlusive disease, and general poor health. All patients were examined with continuous wave Doppler and color duplex ultrasound for anatomic feasibility; patients with duplications and anatomic malformations of the GSV and/or reflux and dilation of several saphenofemoral branch tributaries beyond the GSV were excluded and other treatment methods were recommended. All patients were treated after extensive informed consent and according to the ethical guidelines of the 1975 Declaration of Helsinki.



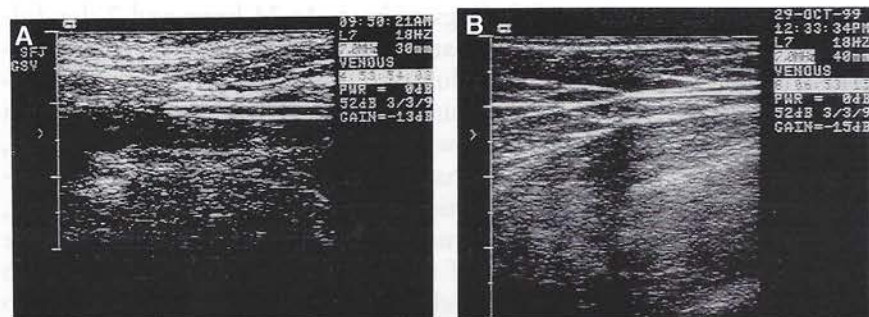
**Figure 1.** Direct introduction of guide wire through exteriorization of greater saphenous vein via stab wound–Mueller hook approach.

Color duplex ultrasound mapping and marking of the affected SFJ and GSV with transverse measurements at 3 cm below the SFJ were performed and recorded. The distance from the point of entry to the SFJ was measured to calculate catheter length and size. The decision for percutaneous or stab wound entry was made depending on the quantity and size of leg branch varicosities, dictating a need for mini-phlebectomy and the individual practitioner's preference. After proper patient positioning on the examination table, betadine skin cleansing, and sterile draping of the leg, the distance between the point of entry and the SFJ was again measured, as positional length variations of 5–10 cm can occur with the standing position. Using local anesthesia (1–2 cc of lidocaine 1% without epinephrine) and under ultrasound guidance, the GSV was subsequently entered on the lower thigh or at knee level via a percutaneous needle puncture (18-gauge needle) or a stab wound–Mueller hook approach (Figures 1 and 2). A



**Figure 2.** Percutaneous placement of a no. 5 French catheter with confirmation of exact laser fiber location through direct visualization of aiming beam, ultrasound guidance, and steri-strip markings of proper catheter and fiber length.





**Figure 3.** A) Ultrasound appearance of no. 5 French catheter as it is positioned within the proximal GSV below the SFJ. B) Ultrasound appearance of the laser fiber in the proximal GSV.

no. 5 or 5.5 French catheter was placed over a 0.035 inch diameter J guide wire and properly positioned within the GSV and confirmed by aspiration of nonpulsatile venous blood and ultrasound visualization (Figure 3A).

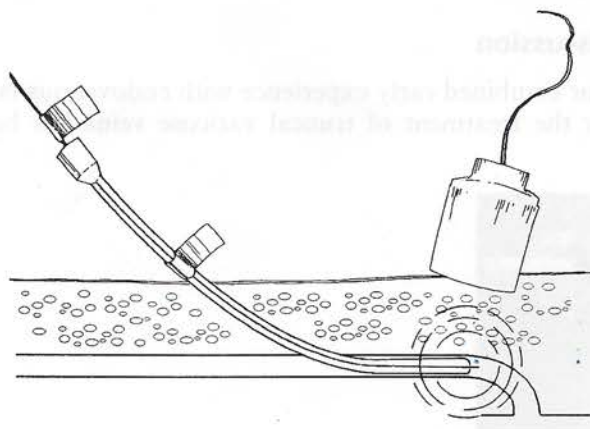
A sterile, bare-tipped laser fiber, 400–750  $\mu$ m in diameter, was introduced into the vein through the catheter. Fiber size was chosen according to catheter diameter, such that the fiber was easily maneuverable inside the catheter. The distal tip of the laser fiber was positioned 1–2 cm below the SFJ and confirmed in three ways: by direct visualization of the red aiming beam of the laser fiber through the skin (Figure 4), with ultrasound guidance (Figure 3B), and by previous marking of the distance between the point of entry to the SFJ onto the catheter and the fiber with steri-strips (Figure 2). Any inadvertent slippage of the laser fiber forward into the common femoral vein or backward into the catheter results in an immediate loss of the visualization of the aiming beam through the skin. Perivenous local anesthesia (30–60 cc of lidocaine 0.5% without epinephrine) was administered at the SFJ and along the GSV, with proper plane infiltration made easy by ultrasound guidance. Vein emptying was facilitated by Trendelenburg positioning and manual finger pressure was applied to oppose the vessel walls around the laser fiber tip (Figure 5).

A wavelength of 810 nm diode laser energy was delivered endovenously 1–2 cm below the SFJ and along the course of

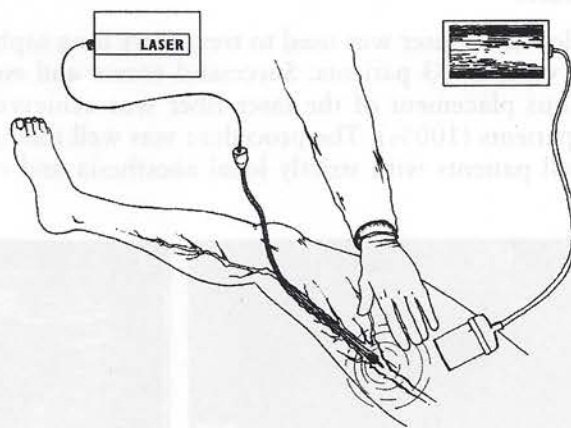
the GSV as the laser fiber and catheter were slowly withdrawn in 3–5 mm increments. The parameters were as follows: 10–14 W in continuous mode with bursts of laser energy 1–2 seconds in duration, for a fluence equivalent to 10–28 J, with an average single continuous burst of 15–20 J. These settings produced focal thermal injury to the endothelium and vein wall extending to the adventitia (Figure 6).

Class II (30–40 mm Hg) graduated compression stockings were applied and worn until the initial follow-up visit and then for a minimum of 7 days following treatment. Patients were instructed to walk immediately following the procedure and to continue their normal daily activities with the exception of vigorous workouts. No postprocedure pain medication was needed. A continuous wave Doppler examination and duplex imaging were performed at 24 hours, 1 week, and various monthly intervals following the initial treatment. After closure of the GSV, sclerotherapy was performed as needed to close remaining branch varicosities.

A group of 80 patients with competent SFJ and GSV and isolated large branch varicosities (Giacomini, anterolateral branch, etc.), with a mean diameter of 5 mm and a mean length of 20 cm, were treated in Spain with endovenous laser therapy after being given the choice of sclerotherapy or ambulatory phlebectomy. Multiple percutaneous introductions of a 600  $\mu$ m bare-tip laser fiber through a no. 16 Med-

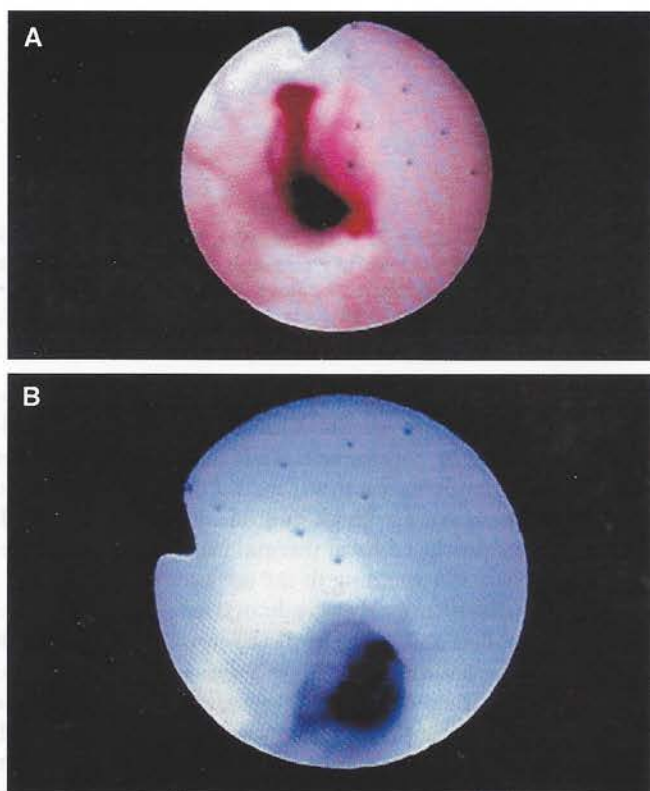


**Figure 4.** Aiming beam clearly visible through the skin facilitates the exact positioning of the tip of the laser fiber.



**Figure 5.** Illustration shows Trendelenburg position of the patient, endovenous catheter, intracatheter passage of the laser fiber, visual and ultrasound confirmation of the position of the laser tip, and manual compression for better laser-fiber endothelial contact.





**Figure 6.** A, B) Endoluminal image of saphenous vein showing point-like marks in the endothelium during the endolaser procedure.

icath were performed along as much of the length of each vein as feasible under local anesthesia (lidocaine 0.5% without epinephrine). A wavelength of 810 nm diode laser energy was delivered at 3–4 W continuous mode in 1–2-second bursts and 3–5 mm increments, for a fluence of 3–8 J. Class I graduated compression stockings were applied and worn until the initial follow-up visit.

## Results

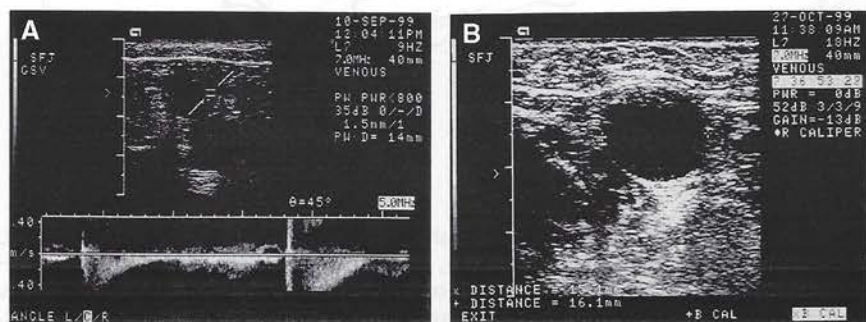
Endovenous laser was used to treat forty long saphenous veins in 33 patients. Successful access and endovenous placement of the laser fiber was achieved in all patients (100%). The procedure was well tolerated by all patients with strictly local anesthesia and only

occasional feelings of heat. At 24-hour and 7-day follow-ups, most patients had mild ecchymosis and occasional mild induration in the area of anesthetic infiltration and/or mini-phlebectomy, more commonly in the latter. There were no point of entry complications, such as hematoma, infection, etc., as well as no heat-related complications of GSV surrounding structures, such as skin burns, paresthesias, cellulitis, etc. There were no cases of thrombophlebitis of the GSV, deep vein thrombophlebitis, or pulmonary emboli, and no allergic reactions. All 40 treated GSV segments were closed (100%) following initial endovenous treatment, as defined by no detectable flow by color duplex ultrasound interrogation and continuous wave Doppler examination at 24 hours, 7 days, and various intervals up to 14-months follow-up, with a mean follow-up time of 4.2 months. No patients required retreatment. All patients were satisfied with the decision to undergo endovenous laser treatment and the subsequent results. Figure 7 shows the ultrasound evaluation of a patient demonstrating the typical appearance of SFJ incompetence with GSV reflux. Figure 8 shows an absence of blood flow and a comparative decrease in GSV diameter 3 cm below the SFJ and at mid thigh, and the typical “cul-de-sac” image of a closed GSV at the SFJ without reflux, but flow from other competent SFJ branches in the same patient 4 and 5 months following endovenous laser treatment. Figure 9 shows the corresponding appearance of this patient’s left lower extremity prior to and 4 months following endovenous laser treatment and three sessions of branch sclerotherapy.

All 80 isolated significant branch varicosities (Giacomini, anterolateral branch, etc.) treated with endolaser have remained closed in a mean follow-up period of 18 months, with only one case of mild pigmentation in skin type III/IV which has slowly subsided. There have been no skin burns.

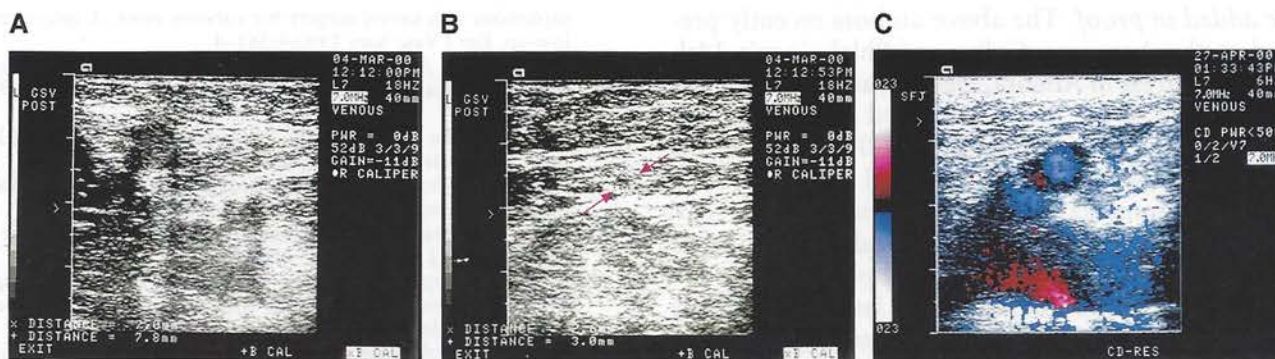## Discussion

Our combined early experience with endovenous laser for the treatment of truncal varicose veins has been



**Figure 7.** Preprocedure ultrasound. A) Documentation of left SFJ incompetence. B) Size of the GSV 3 cm below the SFJ (15.1 mm × 16.1 mm).





**Figure 8.** Ultrasound 4 months post-endolaser shows complete closure and diminished size of GSV at: A) 3 cm below the SFJ (7 mm  $\times$  7.8 mm), and B) mid thigh. C) Color ultrasound 5 months post-endolaser shows typical "cul-de-sac" image at termination of the closed GSV at the SFJ and an absence of reflux but flow from other competent SFJ branches.

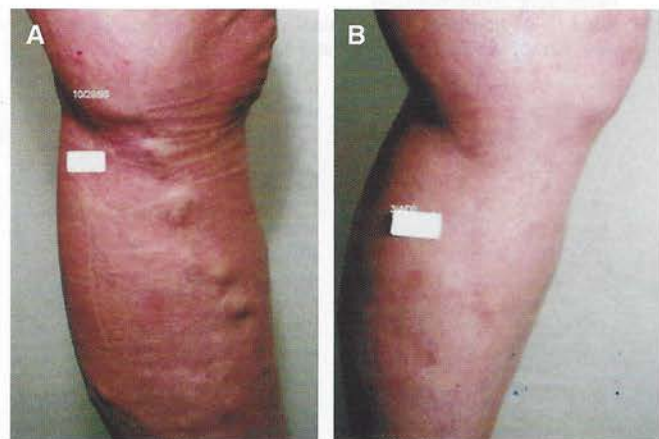very favorable. This minimally invasive technique is performed under strictly local anesthesia in the office with readily available diode laser and laser fibers produced by multiple manufacturers and commonly used in surgical, OB/GYN, and cosmetic dermatology practices. Endolaser is hemodynamically sound, addressing both the point of reflux and the incompetent segment.

Transmission of energy through a small-diameter, flexible fiber (400–750  $\mu$ m) and direct through the skin visualization of the laser tip by its aiming beam light affords easy maneuverability, confidence in the exact placement of the fiber, and minimal access site size—all contributing to procedural ease, controlled execution, and consequently to procedural safety. As is the case with other minimally invasive techniques, the use of strictly local anesthesia eliminates most of the general risks associated with surgery. In our hands the procedure has proven to be very safe, although numbers have been relatively small. Still, a minimum

of skills is required: practitioners should be able to comfortably perform ultrasound-guided sclerotherapy and/or mini-phlebectomy to safely execute this technique.

Our short-term results (mean follow-up 4.2 months)—closure of all treated GSVs with no recanalization and no significant complications—compare favorably to the results of other minimally invasive techniques. Long-term results of the endolaser procedure will depend on two factors: the still unknown percentage of recanalization of the GSV, and patient selection to minimize the long-term consequences of the lack of proper groin dissection. Although the long-term role of leftover competent SFJ branches is not yet known, patients that have reflux and dilatation of several SFJ tributaries besides the GSV will obviously be more prone to failure by this type of treatment and should be treated by standard ligation and stripping. Likewise, all patients with duplications and malformations of the GSV, hunter canal perforators, etc., should benefit from surgery. Endovenous laser should be directed to a wide group of patients with SFJ and GSV incompetence without other SFJ incompetent branch tributaries, with more advanced and complex cases being treated by standard modern ligation and stripping.

This methodology appears to be a safe, well-tolerated, in-office procedure, with preliminary short-term results demonstrating effective closure of incompetent varicose vein segments, including the incompetent GSV. Continued evaluation of different wavelength laser sources and long-term follow-up results are needed to further define the role of endovenous laser as a minimally invasive alternative treatment to ligation and stripping for those patients wishing to avoid surgery.



**Figure 9.** A) A 52-year-old woman prior to endovenous laser treatment. B) Results 4 months after endolaser procedure of the left leg GSV followed by three sessions of sclerotherapy.

**Acknowledgments** All work was performed at The Vein Treatment Center, New York, New York, and The Vein Treatment Center, Palma de Mallorca, Spain.



**Note added in proof.** The above authors recently presented at the American College of Phlebology's 14th Annual Congress in Atlanta, Georgia an 18 month follow-up report of the first 125 treated greater saphenous veins with a mean follow-up of 7.0 months. In this series, recanalization remains 0%, and there were only two cases of immediate partial non-closure of the GSV (both subsequently retreated and closed) and two cases of stasis branch varicosity superficial phlebitis.

In addition to the 810 nm diode laser, the authors have been using a 940 nm diode laser as energy source.

## References

1. Rivlin S. The surgical cure of primary varicose veins. *Br J Surg* 1975;62:913-7.
2. Trendelenburg F. 'ber die Unterbindungen der V. saphena magna bei Unterschenkelvarizen. *Beitr Klin Chir* 1891;7:195-210.
3. Jacobsen BH. The value of different forms of treatment for varicose veins. *Br J Surg* 1979;66:182-4.
4. Koyano K, Sakaguchi S. Selective stripping operation based on Doppler ultrasonic findings of primary varicose veins of the lower extremities. *Surgery* 1988;103:615-9.
5. Corbett CR, Runcie IJ, Thomas ML, Jamieson CW. Reasons to strip the long saphenous vein. *Phlebologie* 1988;41:766-9.
6. Goren G, Yellin AE. Ambulatory stab evulsion phlebectomy for truncal varicose veins. *Am J Surg* 1991;162:166-74.
7. Tibbs DJ, Fletcher EW. Direction of flow in superficial veins as a guide to venous disorders in the lower limbs. *Surgery* 1983;93:758-67.
8. Larsson RH, Lofgren E, Myers TT, Lofgren KA. Long-term results after vein surgery: study of 1000 cases after 10 years. *Mayo Clin Proc* 1974;49:114-7.
9. McMullin GM, Coleridge Smith PD, Scurr JH. Objective assessment of high ligation without stripping the long saphenous vein. *Br J Surg* 1991;78:1139-42.
10. Munn SR, Morton JB, Macbeth WA, Mcleish AR. To strip or not to strip the long saphenous vein? A varicose veins trial. *Br J Surg* 1981;68:426-8.
11. Negus D. Should the incompetent saphenous vein be stripped down to the ankle? *Phlebologie* 1987;40:753-7.
12. Sarin S, Scurr JH, Coleridge Smith PD. Assessment of stripping the long saphenous vein in the treatment of primary varicose veins. *Br J Surg* 1992;79:889-93.
13. Einarsson E. Compression sclerotherapy of varicose veins. In: Eklöf B, Gjöres JE, Thulesius O, et al., eds. *Controversies in the management of venous disorders*. London: Butterworth, 1989:203-11.
14. Hammarsten J, Pedersen P, Cederlund CG, Campanello M. Long saphenous vein saving surgery for varicose veins. A long-term follow-up. *Eur J Vasc Surg* 1990;4:361-4.
15. Ramelet AA. Ambulatory phlebectomy by the Muller method: technique, advantages, and disadvantages. *J Malad Vasc* 1991;16:119-22.
16. Fratila A, Rabe E, Kreysel HW. Percutaneous minisurgical phlebectomy. *Semin Dermatol* 1993;12:117-22.
17. Goren G, Yellin AE. Primary varicose veins: topographic and hemodynamic correlations. *J Cardiovasc Surg* 1990;31:672-7.
18. Bishop CC, Jarrett PE. Outpatient varicose vein surgery under local anesthesia. *Br J Surg* 1986;73:821-2.
19. Bergan JJ. Surgical procedures for varicose veins: axial stripping and stab avulsion. In: Bergan JJ, Kistner RL, eds. *Atlas of venous surgery*. Philadelphia: WB Saunders, 1992:61-77.
20. Bergan JJ. Saphenous vein stripping by inversion. *Surg Rounds* 2000;23:118-24.
21. Conrad P. Groin-to-knee downward stripping of the long saphenous vein. *Phlebologie* 1992;7:20-22.
22. Reid RG, Rothnie NG. Treatment of varicose veins by compression sclerotherapy. *Br J Surg* 1968;55:889-95.
23. Dejode LR. Injection compression treatment for varicose veins. *Br J Surg* 1970;57:285-6.
24. Bishop CCR, Fronek HS, Fronek A, et al. Real-time color duplex scanning after sclerotherapy of the greater saphenous vein. *J Vasc Surg* 1991;14:505-10.
25. Cloutier G. La sclérose des croses des saphènes internes et externes avec compression. *Résultats. Phlebologie* 1980;33:731-5.
26. Clutier G, Zummo M. La sclérose des croses avec compression. *Résultats à long terme. Phlebologie* 1986;39:145-8.
27. Raymond-Martimbeau P. Two different techniques for sclerosing the incompetent saphenofemoral junction: a comparative study. *J Dermatol Surg Oncol* 1990;16:626-31.
28. Biegeleisen K, Neilsen RD, O'Shaughnessy A. Inadvertent intra-arterial injection complicating ordinary and ultrasound-guided sclerotherapy. *J Dermatol Surg Oncol* 1993;19:953-8.
29. Chandler JG, Pichot O, Sessa C, Schuller-Petrovic S, Kabnick LS, Bergan J. Treatment of primary venous insufficiency by endovenous saphenous vein obliteration. *Vasc Surg* 2000;34:201-14.
30. Min RJ, Navarro L. Transcatheter duplex ultrasound-guided sclerotherapy for treatment of greater saphenous vein reflux: preliminary report. *Dermatol Surg* 2000;26:410-13.
31. Kanter A. Clinical determinants of ultrasound-guided sclerotherapy outcome. Part I: the effects of age, gender, and vein size. *Dermatol Surg* 1996;24:131-5.
32. Grondin L. Echosclerotherapy of saphenous axis with microfoam agents [abstract]. 13th Annual Congress of the American College of Phlebology, Scottsdale, Arizona, November 1999.
33. Goldman M. Closure of the greater saphenous vein with endoluminal radiofrequency thermal heating of the vein wall in combination with ambulatory phlebectomy: preliminary 6-month follow-up. *Dermatol Surg* 2000;26:452-6.
34. Boné C. Tratamiento endoluminal de las varices con laser de Diodo. Estudio preliminar. *Rev Patol Vasc* 1999;V:35-46.